

VIRAL ANALYSIS IN A CASE OF CHRONIC RHINITIS IN A CAPTIVE SPUR THIGHED TORTOISE (*TESTUDO GRAECA*)

A. MARTINEZ SILVESTRE¹, A. RAMIS², N. MAJO², J. SOLER MASSANA¹,
R. MARSCHANG³, F. ORIGGI⁴

¹Catalonian Reptile and Amphibian Rehabilitation Centre (C.R.A.R.C.), 08783 Masquefa, Barcelona, Spain
Crarc_Comam@hotmail.com

²Unitat de Anatomia Patologica, Universitat Autonoma de Barcelona, Spain

³Justus Liebig University Giessen, Germany

⁴University of Gainesville, Florida, USA

Résumé

Les auteurs présentent le cas d'une tortue grecque (*Testudo graeca graeca*) qui est morte avec une symptomatologie de rhinite chronique. Chez cette tortue, qui avait été en contact avec d'autres tortues atteintes de rhinite, il n'a pas été possible d'isoler des herpès-virus à partir d'échantillons prélevés 6 mois auparavant dans les cavités orale et nasale. Peu avant le décès, une prise de sang été réalisée. Elle a permis d'obtenir une positivité avec un titre de 1/64 en séroneutralisation pour l'herpès-virus.

Une étude post-mortem a été réalisée comprenant de l'histologie et des cultures virales sur lignées cellulaires THC (cellules cardiaques de *Terrapene*). Enfin, la technique PCR d'amplification du génome viral a été utilisée à partir de tissus fixés au formol. L'histologie en microscopie électronique a révélé la présence de corps d'inclusion et de particules virales. La PCR a démontré la présence du génome d'un herpès-virus. Dans cette communication les auteurs s'attachent au diagnostic de cette maladie et discutent de la possibilité d'existence de virus saprophytes pouvant compliquer l'isolement des herpès-virus dans certains cas.

Abstract

A case of a Spur-thighed tortoise (*Testudo graeca*) dead with symptoms of chronic rhinitis is presented. Tortoise was contact 6 months before with other affected tortoises and was sampled for viral isolation with negative results. Before dead, blood sampling was made for viral seroneutralization that showed of 1/64 titre. In the necropsy of tortoise histopathological studies and viral cultures in THC cellular line were made. PCR techniques were also applied for detection of viral genome in formalin fixed tissues. Inclusion bodies were detected by histopathological examination and electronic microscopy revealed herpesviral particles in the tissues. PCR technique was demonstrated the presence of herpesviral genome. In this communication is presented the utility of different techniques in diagnosis of chronic rhinitis. Is also important the possibility of the presence of an unknown virus that made a competence with the herpesvirus and difficult to isolate them in any occasions.

Key words: diagnose, rhinitis, herpesvirus, spur-thighed tortoise, *Testudo graeca*

Case report

A adult (more than 20 years) female spur-thighed tortoise (*Testudo graeca*) with no clinical signs had been living in a colony of young spur-thighed tortoises with symptoms of rhinitis (upper respiratory tract disease) for 2 years. Tracheal swabs were collected from all the tortoises in the collection mentioned above and delivered to the laboratory for virus isolation attempts. None of the tortoises resulted positive. The old female tortoise was transferred to the Catalonian Reptile and Amphibian Rehabilitation Centre (CRARC) for conservation programs. Six month after the tortoise showed clinical signs of Rhinitis. Nasal cytology revealed a proliferation of lymphocytes and heterophils in the mucus. Blood chemistry and haematological analysis were performed and are summarized in table 1 and 2 below.

The plasma sample collected from the tortoise was also tested for the presence of serum neutralizing antibodies anti-herpesvirus using a serum neutralization (SN) test developed in Germany (Marschang et al., 1997). The tortoise resulted positive and the SN titre was 1/64. According the result from this serological test the tortoise was considered exposed to a herpesvirus infection.

Three days later, the tortoise died and a complete post-mortem investigation was performed. During the necropsy of tortoise, tissue samples were collected for histopathological and viral investigation. *Terrapene* heart cells (TH-1) were selected for the virus isolation attempt. A polymerase chain reaction (PCR) recently developed for the detection of herpesvirus DNA in tissues samples (Origgi et al., 2000) was also used on

formalin fixed paraffin embedded tissues collected during the necropsy.

At light microscopy, amfophilic intranuclear inclusion bodies were detectable in the epithelium of the trachea, larynx and tongue. Electronic microscopy revealed the presence of icosaedric viral particles of 120 nm in size. The virions size and the morphology along with the cytophatic effects shown in cell culture, were identified as herpesvirus. The PCR technique demonstrated the presence of herpesviral DNA.

Discussion

Seven different techniques were made in this case for the diagnosis of herpesviral infection in a tortoise. The following discusses some of the advantages and risk of mistakes of each one of these techniques.

Clinical signs: It was impossible to make a diagnosis of viral rhinitis upon clinical signs only. More diagnostic tools are needed for a successful differential diagnosis between sinusitis (Schumacher 1997), mycoplasmal and other bacterial rhinitis (Brown et al. 1999), rhinitis secondary to pneumonia (Jacobson 1998) or iridovirus infection (Marschang et al. 1998).

Haematology: An easy technique, but it does not permit the detection viruses. Cellular changes in leucocyte count can means an immune response to a microbial agent, but is a unspecific response. In this case was possible to detect an immune activation to septic process (depletion of eosinophils, increase of lymphocytes) and a hypercholesterolaemia due to long term captive conditions (Muro et al. 1998; Martínez Silvestre et al. 1999).

Cytology: Is a good method for finding out what kind of cells are participating in the infectious process. In some cases it is possible to detect inclusion bodies in nasal cytology but it is very difficult (Martínez Silvestre 1999). In this case this was not possible.

Viral Isolation in Terrapene Heart Cell (TH-1): Critical for virus isolation is the collection and the handling of the clinical sample. The presence of other viruses in the clinical samples might impair the growth of the herpesvirus in the same cell culture. Although the technique allows the diagnosis or confirmation of the presence of viral participation, it is also possible to detect other viruses in the same culture making interpretation of results difficult or misinterpreting the results. An unknown virus has been shown to compete with herpesviruses in cell culture, making the isolation of herpesviruses difficult in some cases (Marschang et al. 1998).

Serum neutralization: It is a serological test developed in Germany. This technique can be carried out with a blood sample. It allows to detect the exposure of tortoises to herpesvirus. A plasma sample is required to run the test. A titre of 1/64 is considered suspicious for herpesvirus infection or recent contact. Serological testing for herpesvirus is only available in a few laboratories. It can aid in discriminating asymptomatic

silent carriers of herpes viral rhinitis (Marschang et al. 1997).

PCR and ELISA techniques: Only available in USA, Polymerase Chain Reaction (PCR), ELISA and immunoperoxidase based tests techniques are of great value in detection of viral presence in the tissues. Elisa sensitivity and specificity have been shown to be higher than 97% (Origgi & Jacobson 1999).

Histopathology techniques: Histopathological investigation provide a valuable diagnostic tool to confirm the presence of intranuclear inclusions consistent with herpesvirus infection in the affected tissues. This technique can be extended to include electron microscopy. Electron microscopy provide a powerful diagnostic tool that allows to directly visualize the virions (Martínez Silvestre et al. 1999). Electron microscopy is limited by the quality of the tissue submitted and the number of recognizable herpesvirus particles in it. In this case, presence of herpesviruses was confirmed and photographed.

Conclusion

This case report discusses the possible presence of captive *Testudo graeca* as clinically silent carriers of herpesvirus infection. Testing the tortoises for herpesvirus infection is critical before release them in the wild. Tortoises should not be released in nature before the application of a minimum of three diagnostic techniques for the confirmation of the viral absence.

According the authors, the easiest adoptable protocol for viral rhinitis diagnosis is the following (Drury et al. 1999; Martínez Silvestre et al. 1999; Origgi et al. 2000):

Individual:

Alive: Blood sample for a complete haematology, blood chemistry and serology study, as well as mucus cytology are optional techniques. While certainly possibly clinically relevant, can not considered valid tests for diagnosing herpesvirus infection. **Virus isolation** from pharyngeal swabs can be used in acute infections. Hepatic, lingual or tracheal biopsy techniques could be tested for in vivo diagnosis with the same techniques applied in dead tortoises. But, at now, these techniques have a doubtfully value.

Death: **Histology**, with electronic microscopy diagnosis and PCR techniques are the most feasible techniques.

Virus isolation can complement histology.

Group:

Sample a representative selection of the group for antibody detection. **Serological studies** are useful but the results depend strongly on the species being examined (*Testudo hermanni* are almost always negative, but it does not occur with *T. graeca* or *T. marginata*). Titres can also vary quite strongly over time, so that it can be useful to test several times over the course of a few months. One or two tortoises could be euthanasied for diagnostic techniques as described for dead tortoises.

References

- Brown M.B., McLaughlin G.S., Klein P.A., Crenshaw B.C., Schumacher I.M., Brown D.R., and Jacobson E.R. (1999) Upper respiratory tract disease in the gopher tortoise is caused by *Mycoplasma agassizii*. *Journal of Clinical Microbiology*, 2262:2269.
- Drury S.E.N., Gough R.E., Kay A.V., and McArthur S.D.J. (1999) Detection and isolation of a herpesvirus from a spur-thighed

tortoise (*Testudo graeca*) in the UK. *Veterinary Record*, 145:586-588.

Jacobson E.R. (1998) Respiratory disease in chelonians. *TNAVC Proceedings*, 789-790.

Marschang R.E., Gravendyck M. and Kaleta E.F. (1997) Herpesviruses in tortoises: investigation into virus isolation and the treatment of viral stomatitis in *Testudo hermanni* and *Testudo graeca*. *J. Vet. Med.*, 44:385-394.

Marschang R.E., Posthaus H., Gravendyck M., Kaleta E.F. and Bacciarini L.N. (1998) Isolation of viruses from land tortoises in Switzerland. *Proceedings A.A.Z.V. and A.A.W.V. Joint Conference*, 281-284.

Martínez Silvestre A., Mateu de Antonio E., Ramis A. and Majó N. (1999) Etiología y descripción clínica de la rinitis crónica en tortuga mora (*Testudo graeca*). *Rev. Esp. Herp.*, 13:27-36.

Merchán M. and Martínez Silvestre A. (1999) *Tortugas de España*. Antiquaria, Madrid.

Muro J., Ramis A., Pastor J., Velarde R., Tarres J. and Lavín S. (1998) Chronic rhinitis associated with herpesviral infection in captive spur-thighed tortoises from Spain. *Journal of Wildlife Diseases*, 34(3):487-495.

Origi F., Jacobson E.R., Romero C.H. and Klein P.A. (2000) Diagnostic tools for herpesvirus detection in chelonians. *Proceedings of the A.R.A.V.*, 7:127-129.

Origi F.C. and Jacobson E.R. (1999) Development of an ELISA and an immunoperoxidase based test for herpesvirus exposure detection in tortoises. *Proceedings of the A.R.A.V.*, 6:65-67.

Schumacher J. (1997) Respiratory diseases of reptiles. *Seminars in Avian and Exotic Pet Medicine*, 6(4):208-215.

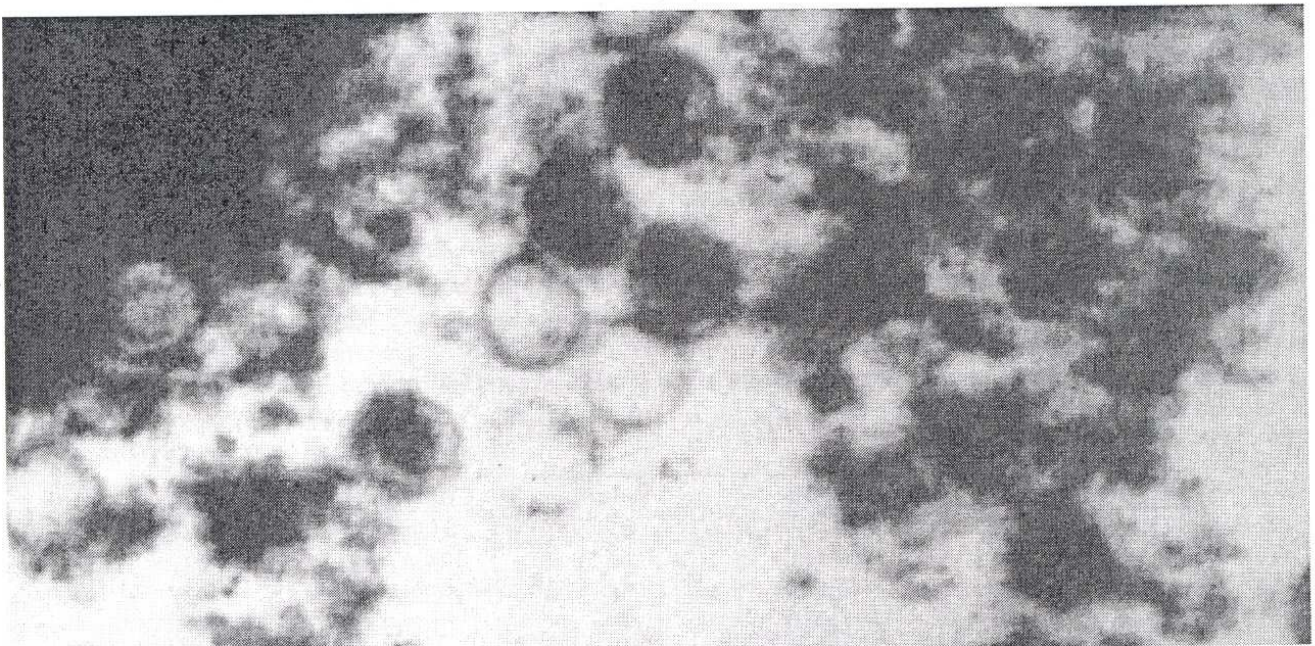


Photo: Viral particles detected in the nose mucosa of a *Testudo graeca* with rhinitis.